Copyright © 2019 by The Journal of Bone and Joint Surgery, Incorporated

Current Concepts Review

Hamstring Injuries

Risk Factors, Treatment, and Rehabilitation

Steven T. Heer, BS, John W. Callander, BA, Matthew J. Kraeutler, MD, Omer Mei-Dan, MD, and Mary K. Mulcahey, MD

Investigation performed at Tulane University School of Medicine, New Orleans, Louisiana

- The most predictive factor for hamstring injury is a previous hamstring injury.
- Magnetic resonance imaging is the most useful study for determining the extent of the hamstring injury and whether surgical intervention is warranted.
- Conservative treatment is indicated for acute hamstring strains, partial tears, and single-tendon avulsions.
- Surgical repair of complete proximal hamstring ruptures, both acute and chronic, results in improved outcomes compared with nonoperative management.
- Repair of acute proximal hamstring tendon tears results in better functional outcomes than repair of chronic tears.
- Stretching and strengthening the hamstring tendons with eccentric exercise is useful for physical therapy after injury and may reduce the risk of reinjury.

Hamstring injuries are common among active individuals, and a complete understanding of the epidemiology, risk factors, and rehabilitation is required to facilitate injury recognition and effective management[1]. These injuries most commonly occur in athletes, especially those involved in sports that require high-speed running or kicking, and they can have a substantial impact on overall function and ability to train[2]. Sports in which athletes are particularly susceptible to injury include soccer, football, dancing, and sprinting because of the repetitive kicking or sprinting associated with each[2]. It has been reported that among track and field athletes, 26% of all injuries and 12% to 15% of all Australian football and soccer injuries can be attributed to hamstring injuries[2]. The purpose of this Current Concepts Review was to synthesize data from the current literature to provide physicians with the latest information regarding risk factors, diagnosis, treatment, and prevention of proximal hamstring injuries.

Anatomy

The hamstring muscle group consists of the long head of the biceps femoris, the semimembranosus, and the semitendinosus muscles, which make up the posterior fascial compartment of the thigh. These tendons originate from the ischial tuberosity, with the semimembranosus originating from the superolateral region of the ischial tuberosity and the biceps femoris and semitendinosus originating from the inferomedial region of the ischial tuberosity. The semimembranosus inserts at the posterior aspect of the medial tibial condyle; the semitendinosus, at the medial border of the proximal tibial shaft; and the biceps femoris, at the lateral condyle of the tibia and the fibular head lateral to the styloid process (Fig. 1)[3]. The sciatic nerve lies approximately 1 cm lateral to the hamstring muscle group, between the biceps femoris and the adductor magnus, making it vulnerable to injury during hamstring injury or surgery (Fig. 1). The secondary ossification center of the ischial tuberosity fuses between the ages of 15 and 25 years, placing it at high risk for avulsion injuries[4].

Risk Factors

There are 2 main types of hamstring injury: muscle belly tears and acute avulsions at the proximal origin of the tendon.

Disclosure: The authors indicated that no external funding was received for any aspect of this work. On the **Disclosure of Potential Conflicts of Interest** forms, *which are provided with the online version of the article*, one or more of the authors checked "yes" to indicate that the author had a relevant financial relationship in the biomedical arena outside the submitted work (http://links.lww.com/JBJS/F148).

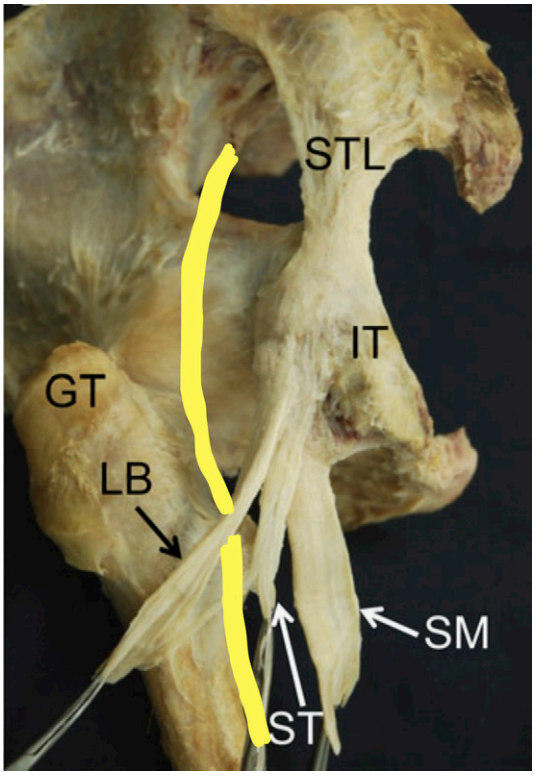

Fig. 1
Anatomy of the proximal hamstring tendons. Three of the hamstring tendons originate on the ischial tuberosity (IT): the semitendinosus (ST), semimembranosus (SM), and long head of the biceps femoris (LB). The yellow line demonstrates the path of the sciatic nerve in relation to these tendon attachments. GT = greater trochanter, and STL = sacrotuberous ligament. (Reproduced from: J Orthop Sci. 2012 Sep;17[5]:614-8. Sato K, Nimura A, Yamaguchi K, Akita K. Anatomical study of the proximal origin of hamstring muscles. Copyright 2012, with permission from Elsevier. https://www.journals.elsevier.com/journal-of-orthopaedic-science.)

Muscle belly tears occur in the muscular portion of the hamstring unit, often at the musculotendinous junction of the biceps femoris, and usually improve with conservative treatment[5,6]. Hamstring avulsions occur when the proximal tendinous attachment separates from its origin on the ischial tuberosity or when there is an osseous avulsion fracture from the tuberosity[7]. In the case of hamstring avulsions, surgery may be indicated, depending on the displacement of the tendon (exceeding 2.5 to 3 cm)[7].

The most predictive factor for a hamstring injury is any previous hamstring injury including sprains, tears, and avulsions[8-11]. Recurrence rates vary by sport, but studies have described recurrence rates of 32% in American football, 21% in rugby, and 16% in soccer[2,12-15]. The primary mechanism of hamstring injury involves high-speed running, and studies have suggested that this injury is a result of the eccentric contraction required of the hamstrings during hip flexion[16]. Injury is primarily due to the stretching and subsequent tension placed on the tendon, thereby making it more susceptible to injury[16]. Additionally, the hamstrings cross 2 joints, the hip and the knee, further stressing these tendons during exercise[2,16,17]. During healing, scar tissue develops and causes decreased flexibility within the tendon, making eccentric contraction more difficult and increasing the likelihood of a subsequent injury in the area of scar formation[9,18,19].

Injuries arising from a single abrupt trauma rather than from smaller cumulative injuries tend to be more serious and affect younger patients during activities such as sprinting and in older individuals during high-risk sports such as water-skiing[20,21]. Long distance running predisposes an individual to chronic tendinopathy, which is likely a result of multiple microscopic events that accumulate and weaken the hamstring tendon, predisposing it to injury[2]. Other nonmodifiable risk factors include older age (>25 years), which has been shown to increase the risk of injury independent of previous injury. While it is unclear why this occurs, the risk increases each year after the age of 25, depending on the sport, with the highest risk being associated with soccer[22]. It has been suggested that aboriginal Australian ethnicity and female sex may be risk factors for these injuries, but there are not enough data available to support this claim[22]. Modifiable risk factors include asymmetric physical strength (both between ipsilateral and contralateral hamstrings and the ratio of strength between the hamstrings and the quadriceps), flexibility, fatigue, and the type of sport (with the highest risk in high-speed running and kicking sports)[2,4,22].

Diagnosis

Evaluation of a patient with a suspected hamstring injury begins with a comprehensive history. The presentation varies, depending on the degree of injury, with tears (both partial and full-thickness) and avulsions presenting relatively similarly and tendinopathies or hamstring strains presenting with more ambiguous pain[23]. Patients with an acute injury often recall the initiating event and may describe feeling a stabbing pain in the posteromedial part of the thigh or hearing a "pop" at the time of injury[23]. Hamstring injuries have a high rate of recurrence, and therefore it is important to assess for similar injuries in the past[2,6,24]. In contrast, patients with hamstring tendinopathy often report a gradual onset of pain with stiffness and cramping in the upper thigh near the buttocks that can extend to the knee[23]. Patients frequently report pain while sitting and performing motions such as tying a shoe or running.

A thorough physical examination should follow, with care taken to evaluate the origin of the muscles at the ischial tuberosity and the insertion point at the tibia and fibula for any palpable defects or pain. In the case of an avulsion or retracted tear, palpation alone may delineate the location of the injury[4]. Patients with acute hamstring injuries may have substantial ecchymosis over the posterior aspect of the thigh (Fig. 2), although this finding is not universal. The patient's flexibility can be evaluated by a passive leg raise, and strength is assessed by evaluating knee flexion strength and hip extension with resistance at both 15° and 90°[23]. Tendinopathies may be assessed using the modified bent-knee stretch test with a sensitivity

Fig. 2
Ecchymosis of the posterior part of the thigh associated with an acute hamstring injury.

of 89% (additional tests and their methods are described in Table I)[25,26]. Pain or tenderness over the hamstrings is considered a positive finding, but it is important to rule out lumbar radiculopathy, hip labral tears, deep gluteal space pathology, and other nonspecific pain disorders since these may present as referred pain. Imaging can be especially useful for distinguishing these disorders from hamstring injuries[4].

Imaging

Hamstring injuries do not always warrant advanced imaging. However, in cases of concerning findings on examination (e.g., ecchymosis or a palpable defect) or failure to improve with conservative treatment, magnetic resonance imaging (MRI) or ultrasound scans may be acquired. If an avulsion injury is suspected, an anteroposterior pelvic radiograph and dedicated ipsilateral hip radiographs are the first imaging studies made to assess for an ischial tuberosity avulsion fracture, although radiographs are typically not useful for diagnosing other hamstring injuries[6,27-29]. It is also worth noting that between 14% to 45% of clinically positive diagnoses of any type of hamstring injury (including both muscle and tendon tears) show no abnormalities on MRI[27,30-33]. A 3-level grading scale is used to evaluate hamstring injuries on MRI. Grade-1 injuries demonstrate macroscopic damage to <5% of the muscle (based on an axial slice), but they are associated with symptoms on physical examination (muscle strains) (Fig. 3-A)[27]. Grade-2 injuries demonstrate visible damage to the muscle fascicles and are referred to as partial tears (5% to 50% of the muscle thickness) (Fig. 3-B). Grade-3 injuries are complete tears or avulsions (Fig. 3-C)[4]. A different classification system exists for ultrasound diagnosis of hamstring injuries, with the main difference being that a grade 0 on ultrasound denotes a normal appearance, while grade 1 is associated with faint signs of injury. Both MRI and ultrasound have been shown to be effective diagnostic techniques[23].

The benefits of acquiring MRI include easier visualization of deep tears and, in the patients with recurrence, the ability to more accurately differentiate previous scar tissue from the acute injury[23]. MRI is also more sensitive than ultrasound in discerning injuries involving <5% of the muscle thickness (grade 1)[27]. The main advantages of ultrasound include low cost, easy accessibility, and the ability to visualize muscle tears at initial presentation, although accurate diagnosis on ultrasound is heavily operator-dependent[23,27]. There is debate about the appropriate timing for acquiring an MRI scan or ultrasound study, with most investigations suggesting that injury grading is more accurate within the first 72 hours[12,34]. In general, improved tear visualization can be achieved on imaging after the acute edema subsides, typically between 1 and 3 days following the injury[6,27].

The appearance of the hamstring tendons on MRI or ultrasound depends on the extent of the damage. In the setting of an acute injury, edema can be visualized on MRI or ultrasound around the musculotendinous junction[4,23,29]. In patients with a partial tear, care must be taken to properly assess the extent of injury, particularly because imaging findings can be easily misinterpreted as tendinitis or bursitis[4]. In patients with an avulsion injury, the ruptured tendon edge often is localized within a hematoma, which can make it difficult to visualize on ultrasound; however, MRI should easily be able to delineate the tendon[4]. Grade-1 strains may be difficult to distinguish from healthy muscle fibers, although MRI scans may demonstrate a "feathery" appearance distally with edema around the ischial

TABLE I Physical Examination Tests for Diagnosing Proximal Hamstring Injuries[26]

Test	Method	Sensitivity *(%)*	Specificity *(%)*
Modified bent-knee stretch test	The patient is positioned supine with the legs fully extended. The hip and knee are then maximally flexed before rapidly extending the knee. Pain in the posterior aspect of the thigh indicates a positive test.	89	91
Puranen-Orava	While the patient stands, the hip is flexed to 90°; the knee is then fully actively extended, and the heel is held on a support such as a table or chair. Pain in the posterior aspect of the thigh indicates a positive test.	76	82
Original bent-knee stretch test	With the patient supine, the hip and knee of the symptomatic extremity are maximally flexed, and the knee is then slowly passively extended. Pain in the posterior aspect of the thigh indicates a positive test.	84	87

Fig. 3

Figs. 3-A, 3-B, and 3-C MRI scans of hamstring injuries according to the 3-level grading scale, showing the biceps femoris tendon (white arrow), the combined semimembranosus and semitendinosus tendons (black arrow), ischial tuberosity (white arrowhead), and sciatic nerve (black arrowhead). **Fig. 3-A** Coronal T2-weighted fat-saturated image demonstrating a grade-1 hamstring injury. **Fig. 3-B** Coronal T2-weighted fat-saturated image demonstrating a grade-2 hamstring injury. **Fig. 3-C** Coronal short tau inversion recovery (STIR) fat-saturated MRI demonstrating a grade-3 hamstring injury. Injuries with >75% involvement of the proximal hamstring tendon indicate a poor prognosis.

tuberosity[23,35]. In the patients with a grade-1 injury, MRI scans are more effective at diagnosis than ultrasound because of the subtler presentation of the injury[36]. On ultrasound studies, hamstring strains can be either hypoechoic or hyperechoic to the surrounding tissue with little structural disruption[4,23]. Partial tears are often found at the deep margins of the muscle, making diagnosis relatively difficult with ultrasound[4].

Treatment

Nonoperative Treatment

Nonoperative treatment is often indicated for acute hamstring strains, partial tears, and single-tendon avulsions. Immediate treatment of injured hamstrings should center around the RICE (rest, ice, compression, and elevation) principle to reduce bleeding and swelling at the affected site[37,38]. Many experts have recommended nonsteroidal anti-inflammatory drugs (NSAIDs) to shorten the return-to-sport times[4,39,40]. The role of NSAIDs in tendon healing is not supported in the literature, and hence these medications should be used primarily as analgesics[40,41]. Physical therapy can be used to rehabilitate nonsurgical injuries to prevent recurrence. These exercises are the same as those used for postoperative rehabilitation as described later in this review. Platelet-rich plasma (PRP) injections have become a popular nonoperative modality as they may promote tendon regeneration by increasing the deposition of a collagen-rich extracellular matrix with high levels of type-I collagen[42,43]. Some studies have suggested using PRP injections in conjunction with physical therapy (to facilitate the mechanical stresses required for organized collagen synthesis) as a viable treatment option for partial hamstring tears and chronic

hamstring tendinopathies with <1 cm of tendon retraction[44-46]. Although this strategy has been suggested, there is also evidence to suggest that PRP injections in conjunction with physical therapy are not superior to physical therapy alone[47-49]. In addition to PRP, intramuscular corticosteroid injections have been shown to reduce the return-to-play times for National Football League (NFL) players with hamstring strains, but data remain scarce and there is concern for potential weakening of the tendon[50,51]. Future recommendations for nonsurgical treatment options may include adding losartan (an angiotensin II receptor blocker) and growth factor injections such as insulin-like growth factor-1 (IGF-1), although clinical evidence supporting their use is limited at this time[4,52].

Operative Treatment

Hamstring tendon avulsions with or without an avulsion fracture of the ischial tuberosity are frequently treated surgically. The primary indication for surgery includes complete avulsion of all 3 tendons, disruption of the conjoined tendon with retraction (exceeding 2.5 cm), or an avulsion fracture with displacement exceeding 1 to 1.5 cm[18,53,54]. Sciatic nerve involvement with a tingling sensation or pain in the posterior aspect of the thigh may also necessitate surgical intervention[18].

Hamstring Tendon Avulsions

Hamstring tendon avulsion injuries tend to occur in athletes, especially in sports involving sprinting or kicking such as soccer, track (sprinting), and football[2]. Treatment of hamstring tendon avulsions usually includes open or endoscopic surgical repair using suture anchors for direct fixation of the tendon to the true footprint on the ischial tuberosity[5,7,18,55]. The repeat rupture rate of suture anchor repair has been cited as 2.7% to 3% at a minimum follow-up time of 12 months[7,56,57]. There is also an increased risk of ischiofemoral impingement in patients who are treated surgically[7,58]. With regard to chronic hamstring avulsions with muscle-tendon retraction and shortening, augmenting repair with an Achilles tendon allograft may help to restore strength and function in patients similar to that of acute injury repairs[59]. A systematic review by Harris et al.[7] demonstrated that surgical repair of both acute (<4 weeks) and chronic (≥4 weeks) complete proximal hamstring ruptures that presented symptomatically resulted in significantly improved outcomes compared with nonoperative management. This same review also found that outcomes in patients treated for acute injuries were better than those in patients treated for chronic injuries, confirming the value of early intervention[7].

Ischial Tuberosity Avulsion Fractures

Compared with hamstring tendon avulsion injuries, ischial tuberosity avulsion fractures are rare, yet often present similarly (Fig. 4). It has been reported that ischial tuberosity avulsion fractures account for 1.4% to 4% of hamstring injuries[60]. These injuries tend to occur in young athletes (from 13 to 16 years old) because of the appearance of the secondary ossification center during puberty, making the apophysis the weakest point in the muscle, bone, and tendon unit[18,61]. Avulsion fractures displaced ≤1 cm can be treated conservatively by avoiding hip flexion and knee extension[18,61]. Early surgical fixation may be indicated in patients with symptomatic nonunion or displacement of >1 cm in order to avoid long-term complications such as chronic pain on sitting (ischiofemoral impingement) or walking or an inability to return to full activity[61]. The standard procedure for more displaced fragments is open reduction and internal fixation[62]. In a retrospective case series reported by Gidwani and Bircher[62], pelvic reconstruction plates were used in 5 of 6 patients with bone autograft from either the greater trochanter or the posterior aspect of the iliac crest. Five of the 6 patients had successful operations, with the sixth needing a revision (because of breakage of the inferior screws) that was ultimately successful. All patients were able to return to their previous level of play within a year following surgery[62]. Summaries of studies describing nonoperative and operative treatment options with outcomes can be found in Table II.

Postoperative Rehabilitation

Postoperative rehabilitation is geared toward limiting stress and tension at the hamstring repair site while gradually allowing for increased hip flexion, knee extension, and weight-bearing[55]. In order to reduce tension and allow proper healing in recently repaired proximal tendon avulsions, some surgeons have recommended that patients wear a brace to prevent unwanted tension at the repair site[53,56,63]. Although some physicians have recommended the use of a bi-joint brace[56] (which secures the lower torso and thigh) to reduce both hip and knee mobility, others have recommended the use of only a hinged knee brace, reducing the debilitating effects associated with keeping the hip braced in extension[53,63]. A hinged brace keeps the knee immobilized in a flexed position (sometimes up to 90°)

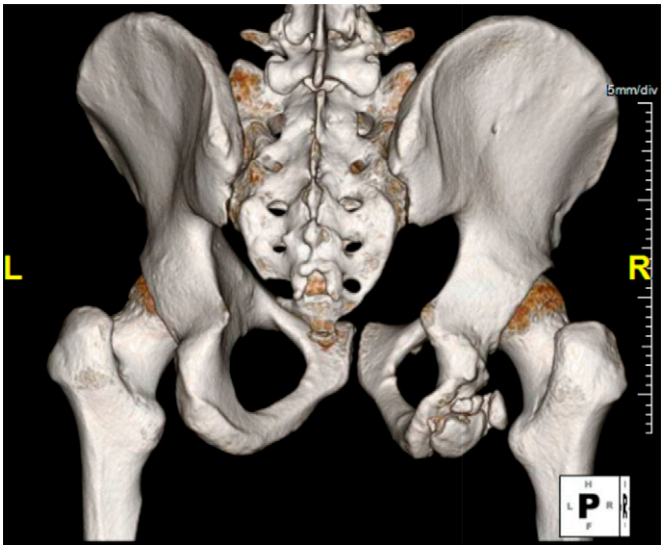

Fig. 4
Three-dimensional computed tomography scan of a right ischial tuberosity avulsion fracture.

TABLE II Summary of Important Studies and Level of Evidence*

	Summary of Intervention and/or Findings	Results	Study Population (no. of participants)	Type of Study (Level of Evidence)
Nonoperative treatment of hamstring injuries				
Reurink et al.[49] (2014)	Slump stretching and calf blood extract injections are not supported in the literature for improving hamstring injury recovery time	A systematic review of RCTs did not show adequate evidence for the usefulness of slump stretching and calf blood extract injections in speeding up recovery from hamstring injury	NA	Systematic review of RCTs (I)
A Hamid et al.[45] (2014)	Rehabilitation for hamstring injury is more effective when combined with a single PRP injection	Patients receiving the PRP injection recovered more quickly than the control group (p = 0.02)	Patients ≥18 years old who presented to clinic with suspected acute hamstring injury (n = 80)	RCT (II)
Hamilton et al.[47] (2015)	Athletes with acute, MRI-positive hamstring injury recover at the same speed with or without a PRP injection during intensive rehabilitation	The adjusted difference for time to return to sports between the PRP and no-injection groups was −2.9 days (95% CI, −7.2 to 1.4 days; p = 0.189)	Professional athletes with MRI-positive hamstring injury (n = 90)	Randomized double-blind study (II)
Surgical treatment of tendon avulsions				
Harris et al.[7] (2011)	Surgical repair of proximal hamstring ruptures within 1 mo (acute) improves patients' strength, endurance, and subjective outcome while improving their rate of return to preinjury levels of activity.	Surgical repair of acute injury has better outcomes (endurance, strength, patient satisfaction, pain relief, etc.) than chronic repair (p < 0.001).	NA	Systematic review of Level-I through IV evidence studies (IV)
	Repair after 1 mo (chronic) also improves the above criteria but not as significantly as acute repair.	Acute repair also has fewer complications (p < 0.05).		
	There are lower risks of complications in acute repair	Surgical repair of chronic injury also has improved outcomes but not as good as those after acute repair		
Wood et al.[56] (2008)	Acute hamstring origin avulsion injuries can be treated with surgery for consistently positive outcomes.	After surgical repair, hamstring strength ranged from 43% to 122% compared with the uninjured side (mean = 84%).	Patients with avulsion of the proximal hamstring origin with minimum follow-up of 6 mo (n = 71)	Clinical case series (IV)
	Delaying the surgical repair makes the procedure more challenging and reduces positive outcomes	Hamstring endurance ranged from 26% to 161% compared with the uninjured side (mean = 89%)		
Brucker and Imhoff[93] (2005)	Early suture anchor repair of proximal hamstring tendon avulsion yields satisfactory results	7 of 8 patients were able to return to previous levels of activity at a mean follow-up of 20 mo	Patients with traumatic rupture of proximal hamstring tendon (n = 8)	Retrospective case series (IV)

continued

TABLE II (*continued*)

	Summary of Intervention and/or Findings	Results	Study Population (no. of participants)	Type of Study (Level of Evidence)
Surgical treatment of tuberosity fractures				
Gidwani and Bircher[62] (2007)	Acute hamstring tendon avulsions and displaced ischial apophysis injuries should be treated with surgery	Surgical repair of acute hamstring avulsions and ischial apophysis fractures has good outcomes	Patients with acute hamstring tendon avulsions with ischial apophysis fracture (n = 12)	Retrospective case series (IV)
Physical therapy				
van der Horst et al.[19] (2015)	Nordic hamstring exercises reduce hamstring injuries when used in training regimens	Nordic hamstring exercises reduce the risk of hamstring injury (OR = 0.282, p = 0.005)	Male amateur soccer players (n = 579)	RCT (I)
Arnason et al.[71] (2008)	Flexibility training does not lower the risk of hamstring injury; Nordic hamstring exercises reduce the risk of hamstring injury	Risk of hamstring injury was lower in groups using the Nordic hamstring exercises than in those using flexibility training (RR = 0.43, p = 0.01)	Icelandic and Norwegian professional soccer players (17 teams of 18 to 24 players; teams varied over 4 yr of study)	Prospective study (II)
Sherry and Best[69] (2004)	Athletes with acute hamstring strains have better outcomes in rehabilitation programs focused on progressive agility and trunk stabilization (PATS) compared with rehabilitation focused on isolated hamstring strengthening and stretching	Reinjury rate is greater in rehabilitation isolated to the hamstring than in the PATS programs in the first 2 wk (54.5%, p = 0.00343)	Athletes with acute hamstring strain (n = 24)	Prospective randomized comparison (II)

*RCT = randomized controlled trial, NA = not applicable, PRP = platelet-rich plasma, CI = confidence interval, OR = odds ratio, and RR = relative risk.

to reduce tension on the tendon, and should be used only for a maximum of 8 weeks to minimize knee stiffness[56]. During the first 6 weeks, the patient should gradually increase knee extension every 2 weeks as permitted by hamstring tension combined with toe-touch weight-bearing on crutches[55,56]. It is also important for patients to work on knee extension with the hip extended, as otherwise patients may experience a painful flexion contracture at the hip. At 6 weeks, the patient should be able to bear full weight with the initiation of gait training[55,56]. Isotonic exercises should be performed while avoiding full hip flexion (>110°) during weeks 6 to 10[54]. After 10 weeks, the patient may begin sport-specific rehabilitation exercises (including eccentric exercises outlined below) that are meant to reduce injury recurrence[55].

Physical Therapy to Prevent New and Recurrent Injury

Techniques to prevent new and recurrent injuries should focus on strengthening the hamstrings to allow the tendons to withstand high levels of eccentric forces[64]. Due to the high rates of recurrent hamstring strains, physical therapy should be used for rehabilitation and to reduce the risk of reinjury, especially in patients with chronic hamstring tendinopathy due to shorter hamstring tendon length that results from the healing process[24,65,66]. Several techniques have been described, all of which focus on strengthening the tendon through eccentric and extension exercises of the hip[24,67-70]. Several studies have demonstrated that completing Nordic hamstring exercises immediately after sports training or physical activity has this preventative effect on hamstring injuries among soccer players[19,24,65,66,71,72]. Furthermore, although the overall evidence is limited, progressive agility and trunk stabilization (PATS) programs have shown promising results in reducing injury recurrence rates[69]. These exercises focus on the remodeling phase of the healing process and are designed to remodel and align collagen fibers in the scar tissue[69]. Other methods such as proprioceptive neuromuscular training (balance training) have been studied, with mixed results[73-75]. Summaries of key studies describing physical therapy techniques and outcomes can be found in Table II.

TABLE III Grades of Recommendation for Proximal Hamstring Injury Treatment

Recommendation	Grade of Evidence*
Nonoperative therapy should include the RICE principle and the use of NSAIDs for less serious injuries such as acute strains, partial tears, and single tendon avulsions[4,37-40].	B
Physical therapy should be used to rehabilitate both operatively and nonoperatively treated injuries, with exercises focusing on strengthening tendons to withstand high levels of eccentric forces[19,24,65,66,71,72].	B
Surgical treatment of acute hamstring avulsions with retraction exceeding 2.5 to 3 cm with symptomatic involvement should be managed with open or endoscopic surgical repair using suture anchors, with early intervention yielding better results[7,56,57].	B
Physicians should treat ischial tuberosity avulsion fractures with displacement of >1 cm surgically and use conservative measures for displacement of ≤1 cm[18,60-62].	C

*According to Wright[94], grade A indicates good evidence (Level-I studies with consistent findings) for or against recommending intervention; grade B, fair evidence (Level-II or III studies with consistent findings) for or against recommending intervention; grade C, poor-quality evidence (Level-IV or V studies with consistent findings) for or against recommending intervention; and grade I, insufficient or conflicting evidence not allowing a recommendation for or against intervention.

Clinical Outcomes

There are many factors that affect clinical outcome and time to return to play of both surgical and nonsurgical treatment of hamstring injuries. Some of the factors associated with a longer recovery time include the extent of injury, mechanism of injury (injuries sustained while sprinting are associated with a better prognosis), and the time it takes a patient to walk pain-free (walking pain-free <24 hours after the injury has a better prognosis)[27,76-78]. A history of hamstring injury is associated with a prolonged recovery[78]. The type of sport (recreational athletes tend to have longer recovery times than professionals) and a longer time to the first consultation and treatment (>1 week after initial injury) can also increase the time to full recovery[76,79]. Poor prognostic factors on MRI include involvement of the biceps femoris tendon, complete tendon avulsion with retraction, complete transection or avulsion of the muscle, or a tear involving >75% of the muscle thickness on an axial section[23,76,80,81]. Ultrasound findings such as hematoma, injury to the biceps femoris, substantial longitudinal disruptions (>50%) to the area of the injury, and structural damage all indicate a poor prognosis[76,82]. Previous studies have demonstrated that factors such as age, use of NSAIDs, and grade-1 compared with grade-2 injury do not affect recovery time[23,76,83].

Positive clinical outcomes following hamstring injuries are associated with certain rehabilitation strategies such as extra stretching sessions per day (4 compared with 1) and exercises specifically designed to lengthen muscle fascicles[76]. On imaging, patients have a better prognosis if they present with smaller (<50%) longitudinal disruptions, tears involving <50% of the muscle thickness, injuries that spare the muscle tendons, negative MRI findings, and superficial injuries[76].

There is disagreement about whether the involvement of multiple tendons or the location of the injury (to the muscle belly, tendon, or ischial tuberosity) are poor prognostic factors[30,81]. Additionally, there may be sex-related differences in outcomes. Mohamad Shariff et al.[79] demonstrated that female athletes had a worse prognosis than their male counterparts after conservative treatment of a hamstring strain, while other recent studies have refuted this claim[30,76,78,79,84].

Van der Made et al.[58] described 5 criteria that can be used to assess a patient's ability to return to preinjury activity levels following a proximal hamstring injury of varying severity. These include absence of pain at the injury site, similar strength level (compared with the uninjured leg or using the Lower Extremity Functional Scale), similar flexibility to the uninjured leg, functional outcome scales (based on residual symptoms and levels of activity), and clearance from the medical staff[5,19,58,85-88]. These definitions make it difficult to objectively assess an athlete's rate of return to preinjury activity levels, especially in grade-1 and grade-2 injuries, since these patients often have uneventful recoveries. Maniar et al.[89] reviewed 28 studies on hamstring strength and rehabilitation time and found that patients with grade-1 or grade-2 injuries gained normal leg isometric strength within 20 to 50 days of the initial injury, although the authors recommended continuing physical therapy after return to play to improve eccentric strength[2,90]. However, there is also evidence that suggests that the hamstring eccentric strength deficit remains long after the initial recovery period and might be the reason for recurrent hamstring injuries[89,91]. Grade-1 and grade-2 injuries have been reported to have a recurrence rate of 16% to 32%[2,12-15,19,58]. After surgical intervention for grade-3 injuries, 76% to 100% of athletes were reported to return to play and 55% to 100% of recreational patients returned to their reported preinjury level of activity[58,59,92].

Overview

This review synthesizes current literature on hamstring injuries and can be used to help clinicians to recognize this pathology and initiate appropriate treatment. It is important for physicians and patients to be aware of the potential risk factors for developing a hamstring injury and, when appropriate, take care to mitigate these risks. Hamstring strains and tendinopathies should be treated more conservatively, whereas surgical treatment is indicated for most hamstring tendon avulsion injuries

or ischial tuberosity fractures with substantial displacement. Following treatment, risks of reinjury can be reduced by performing eccentric hamstring tendon strengthening exercises. A better understanding of hamstring injuries will ultimately allow clinicians to provide more effective treatment and improve the safety and recovery of their patients (Table III). ■

Steven T. Heer, BS[1]
John W. Callander, BA[1]
Matthew J. Kraeutler, MD[2]
Omer Mei-Dan, MD[3]
Mary K. Mulcahey, MD[4]

[1]Tulane University School of Medicine, New Orleans, Louisiana

[2]St. Joseph's University Medical Center, Paterson, New Jersey

[3]University of Colorado School of Medicine, Aurora, Colorado

[4]Department of Orthopaedic Surgery, Tulane University School of Medicine, New Orleans, Louisiana

E-mail address for M.K. Mulcahey: mary.mulcahey.md@gmail.com

ORCID iD for S.T. Heer: 0000-0002-4365-9599
ORCID iD for J.W. Callander: 0000-0003-0714-0666
ORCID iD for M.J. Kraeutler: 0000-0002-2276-7814
ORCID iD for O. Mei-Dan: 0000-0001-7555-986X
ORCID iD for M.K. Mulcahey: 0000-0001-6125-8169

References

1. Tyler TF, Schmitt BM, Nicholas SJ, McHugh MP. Rehabilitation after hamstring-strain injury emphasizing eccentric strengthening at long muscle lengths: results of long-term follow-up. J Sport Rehabil. 2017 Apr;26(2):131-40. Epub 2016 Aug 24.

2. Opar DA, Williams MD, Shield AJ. Hamstring strain injuries: factors that lead to injury and re-injury. Sports Med. 2012 Mar 1;42(3):209-26.

3. Sato K, Nimura A, Yamaguchi K, Akita K. Anatomical study of the proximal origin of hamstring muscles. J Orthop Sci. 2012 Sep;17(5):614-8. Epub 2012 Jun 6.

4. Linklater JM, Hamilton B, Carmichael J, Orchard J, Wood DG. Hamstring injuries: anatomy, imaging, and intervention. Semin Musculoskelet Radiol. 2010 Jun;14(2): 131-61. Epub 2010 May 18.

5. Lempainen L, Banke IJ, Johansson K, Brucker PU, Sarimo J, Orava S, Imhoff AB. Clinical principles in the management of hamstring injuries. Knee Surg Sports Traumatol Arthrosc. 2015 Aug;23(8):2449-56. Epub 2014 Feb 21.

6. Heiderscheit BC, Sherry MA, Silder A, Chumanov ES, Thelen DG. Hamstring strain injuries: recommendations for diagnosis, rehabilitation, and injury prevention. J Orthop Sports Phys Ther. 2010 Feb;40(2):67-81.

7. Harris JD, Griesser MJ, Best TM, Ellis TJ. Treatment of proximal hamstring ruptures - a systematic review. Int J Sports Med. 2011 Jul;32(7):490-5. Epub 2011 May 11.

8. Mendiguchia J, Martinez-Ruiz E, Edouard P, Morin JB, Martinez-Martinez F, Idoate F, Mendez-Villanueva A. A multifactorial, criteria-based progressive algorithm for hamstring injury treatment. Med Sci Sports Exerc. 2017 Jul;49(7):1482-92.

9. Jönhagen S, Németh G, Eriksson E. Hamstring injuries in sprinters. The role of concentric and eccentric hamstring muscle strength and flexibility. Am J Sports Med. 1994 Mar-Apr;22(2):262-6.

10. Orchard J, Steet E, Walker C, Ibrahim A, Rigney L, Houang M. Hamstring muscle strain injury caused by isokinetic testing. Clin J Sport Med. 2001 Oct;11(4):274-6.

11. Engebretsen AH, Myklebust G, Holme I, Engebretsen L, Bahr R. Intrinsic risk factors for hamstring injuries among male soccer players: a prospective cohort study. Am J Sports Med. 2010 Jun;38(6):1147-53. Epub 2010 Mar 24.

12. Ekstrand J, Healy JC, Waldén M, Lee JC, English B, Hägglund M. Hamstring muscle injuries in professional football: the correlation of MRI findings with return to play. Br J Sports Med. 2012 Feb;46(2):112-7. Epub 2011 Dec 5.

13. Hawkins RD, Hulse MA, Wilkinson C, Hodson A, Gibson M. The association football medical research programme: an audit of injuries in professional football. Br J Sports Med. 2001 Feb;35(1):43-7.

14. Henderson G, Barnes CA, Portas MD. Factors associated with increased propensity for hamstring injury in English Premier League soccer players. J Sci Med Sport. 2010 Jul;13(4):397-402. Epub 2009 Oct 2.

15. Feeley BT, Kennelly S, Barnes RP, Muller MS, Kelly BT, Rodeo SA, Warren RF. Epidemiology of National Football League training camp injuries from 1998 to 2007. Am J Sports Med. 2008 Aug;36(8):1597-603. Epub 2008 Apr 28.

16. Heiderscheit BC, Hoerth DM, Chumanov ES, Swanson SC, Thelen BJ, Thelen DG. Identifying the time of occurrence of a hamstring strain injury during treadmill running: a case study. Clin Biomech (Bristol, Avon). 2005 Dec;20(10):1072-8. Epub 2005 Aug 31.

17. Chumanov ES, Heiderscheit BC, Thelen DG. Hamstring musculotendon dynamics during stance and swing phases of high-speed running. Med Sci Sports Exerc. 2011 Mar;43(3):525-32.

18. Sherry M. Examination and treatment of hamstring related injuries. Sports Health. 2012 Mar;4(2):107-14.

19. van der Horst N, Smits DW, Petersen J, Goedhart EA, Backx FJ. The preventive effect of the nordic hamstring exercise on hamstring injuries in amateur soccer players: a randomized controlled trial. Am J Sports Med. 2015 Jun;43(6):1316-23. Epub 2015 Mar 20.

20. Sallay PI, Friedman RL, Coogan PG, Garrett WE. Hamstring muscle injuries among water skiers. Functional outcome and prevention. Am J Sports Med. 1996 Mar-Apr;24(2):130-6.

21. Opar DA, Drezner J, Shield A, Williams M, Webner D, Sennett B, Kapur R, Cohen M, Ulager J, Cafengiu A, Cronholm PF. Acute hamstring strain injury in track-and-field athletes: A 3-year observational study at the Penn Relay Carnival. Scand J Med Sci Sports. 2014 Aug;24(4):e254-9. Epub 2013 Dec 15.

22. Prior M, Guerin M, Grimmer K. An evidence-based approach to hamstring strain injury: a systematic review of the literature. Sports Health. 2009 Mar;1(2): 154-64.

23. Chu SK, Rho ME. Hamstring injuries in the athlete: diagnosis, treatment, and return to play. Curr Sports Med Rep. 2016 May-Jun;15(3):184-90.

24. Brooks JHM, Fuller CW, Kemp SPT, Reddin DB. Incidence, risk, and prevention of hamstring muscle injuries in professional rugby union. Am J Sports Med. 2006 Aug;34(8):1297-306. Epub 2006 Feb 21.

25. Reiman MP, Loudon JK, Goode AP. Diagnostic accuracy of clinical tests for assessment of hamstring injury: a systematic review. J Orthop Sports Phys Ther. 2013 Apr;43(4):223-31. Epub 2013 Jan 14.

26. Cacchio A, Borra F, Severini G, Foglia A, Musarra F, Taddio N, De Paulis F. Reliability and validity of three pain provocation tests used for the diagnosis of chronic proximal hamstring tendinopathy. Br J Sports Med. 2012 Sep;46(12):883-7. Epub 2012 Jan 4.

27. Kerkhoffs GMMJ, van Es N, Wieldraaijer T, Sierevelt IN, Ekstrand J, van Dijk CN. Diagnosis and prognosis of acute hamstring injuries in athletes. Knee Surg Sports Traumatol Arthrosc. 2013 Feb;21(2):500-9. Epub 2012 May 24.

28. Koulouris G, Connell D. Imaging of hamstring injuries: therapeutic implications. Eur Radiol. 2006 Jul;16(7):1478-87. Epub 2006 Mar 3.

29. Clanton TO, Coupe KJ. Hamstring strains in athletes: diagnosis and treatment. J Am Acad Orthop Surg. 1998 Jul-Aug;6(4):237-48.

30. Gibbs NJ, Cross TM, Cameron M, Houang MT. The accuracy of MRI in predicting recovery and recurrence of acute grade one hamstring muscle strains within the same season in Australian Rules football players. J Sci Med Sport. 2004 Jun;7(2): 248-58.

31. Verrall GM, Slavotinek JP, Barnes PG, Fon GT, Spriggins AJ. Clinical risk factors for hamstring muscle strain injury: a prospective study with correlation of injury by magnetic resonance imaging. Br J Sports Med. 2001 Dec;35(6):435-9, discussion :440.

32. Verrall GM, Slavotinek JP, Barnes PG, Fon GT. Diagnostic and prognostic value of clinical findings in 83 athletes with posterior thigh injury: comparison of clinical findings with magnetic resonance imaging documentation of hamstring muscle strain. Am J Sports Med. 2003 Nov-Dec;31(6):969-73.

33. Schneider-Kolsky ME, Hoving JL, Warren P, Connell DA. A comparison between clinical assessment and magnetic resonance imaging of acute hamstring injuries. Am J Sports Med. 2006 Jun;34(6):1008-15. Epub 2006 Feb 13.

34. Guermazi A, Roemer FW, Crema MD. Imaging in sports-specific musculoskeletal injuries. Cham, Switzerland: Springer; 2015.

35. Nicholson LT, DiSegna S, Newman JS, Miller SL. Fluoroscopically guided peritendinous corticosteroid injection for proximal hamstring tendinopathy: a retrospective review. Orthop J Sports Med. 2014 Mar 17;2(3):2325967114526135.

36. Koulouris G, Connell D. Hamstring muscle complex: an imaging review. Radiographics. 2005 May-Jun;25(3):571-86.

37. Järvinen TA, Järvinen TL, Kääriäinen M, Aärimaa V, Vaittinen S, Kalimo H, Järvinen M. Muscle injuries: optimising recovery. Best Pract Res Clin Rheumatol. 2007 Apr;21(2):317-31.

38. Guillodo Y, Saraux A. Treatment of muscle trauma in sportspeople (from injury on the field to resumption of the sport). Ann Phys Rehabil Med. 2009 Apr;52(3): 246-55. Epub 2009 Feb 23.

39. Paoloni JA, Milne C, Orchard J, Hamilton B. Non-steroidal anti-inflammatory drugs in sports medicine: guidelines for practical but sensible use. Br J Sports Med. 2009 Oct;43(11):863-5. Epub 2009 Jun 21.

40. Mehallo CJ, Drezner JA, Bytomski JR. Practical management: nonsteroidal antiinflammatory drug (NSAID) use in athletic injuries. Clin J Sport Med. 2006 Mar; 16(2):170-4.

41. Aström M, Westlin N. No effect of piroxicam on achilles tendinopathy. A randomized study of 70 patients. Acta Orthop Scand. 1992 Dec;63(6):631-4.

42. Visser LC, Arnoczky SP, Caballero O, Kern A, Ratcliffe A, Gardner KL. Growth factor-rich plasma increases tendon cell proliferation and matrix synthesis on a synthetic scaffold: an in vitro study. Tissue Eng Part A. 2010 Mar;16(3):1021-9.

43. Alsousou J, Thompson M, Harrison P, Willett K, Franklin S. Effect of platelet-rich plasma on healing tissues in acute ruptured Achilles tendon: a human immunohistochemistry study. Lancet. 2015 Feb 26;385(Suppl 1):S19.

44. Kraeutler MJ, Garabekyan T, Mei-Dan O. The use of platelet-rich plasma to augment conservative and surgical treatment of hip and pelvic disorders. Muscles Ligaments Tendons J. 2016 Dec 21;6(3):410-9.

45. A Hamid MS, Mohamed Ali MR, Yusof A, George J, Lee LP. Platelet-rich plasma injections for the treatment of hamstring injuries: a randomized controlled trial. Am J Sports Med. 2014 Oct;42(10):2410-8. Epub 2014 Jul 29.

46. Davenport KL, Campos JS, Nguyen J, Saboeiro G, Adler RS, Moley PJ. Ultrasound-guided intratendinous injections with platelet-rich plasma or autologous whole blood for treatment of proximal hamstring tendinopathy: a double-blind randomized controlled trial. J Ultrasound Med. 2015 Aug;34(8):1455-63.

47. Hamilton B, Tol JL, Almusa E, Boukarroum S, Eirale C, Farooq A, Whiteley R, Chalabi H. Platelet-rich plasma does not enhance return to play in hamstring injuries: a randomised controlled trial. Br J Sports Med. 2015 Jul;49(14):943-50.

48. Pas HI, Reurink G, Tol JL, Weir A, Winters M, Moen MH. Efficacy of rehabilitation (lengthening) exercises, platelet-rich plasma injections, and other conservative interventions in acute hamstring injuries: an updated systematic review and meta-analysis. Br J Sports Med. 2015 Sep;49(18):1197-205. Epub 2015 Jul 21.

49. Reurink G, Goudswaard GJ, Moen MH, Weir A, Verhaar JA, Bierma-Zeinstra SM, Maas M, Tol JL; Dutch Hamstring Injection Therapy (HIT) Study Investigators. Platelet-rich plasma injections in acute muscle injury. N Engl J Med. 2014 Jun 26; 370(26):2546-7.

50. Levine WN, Bergfeld JA, Tessendorf W, Moorman CT 3rd. Intramuscular corticosteroid injection for hamstring injuries. A 13-year experience in the National Football League. Am J Sports Med. 2000 May-Jun;28(3):297-300.

51. Acevedo JI, Beskin JLT. Complications of plantar fascia rupture associated with corticosteroid injection. Foot Ankle Int. 1998 Feb;19(2):91-7.

52. Terada S, Ota S, Kobayashi M, Kobayashi T, Mifune Y, Takayama K, Witt M, Vadalà G, Oyster N, Otsuka T, Fu FH, Huard J. Use of an antifibrotic agent improves the effect of platelet-rich plasma on muscle healing after injury. J Bone Joint Surg Am. 2013 Jun 5;95(11):980-8.

53. Cohen S, Bradley J. Acute proximal hamstring rupture. J Am Acad Orthop Surg. 2007 Jun;15(6):350-5.

54. Konan S, Haddad F. Successful return to high level sports following early surgical repair of complete tears of the proximal hamstring tendons. Int Orthop. 2010 Feb;34(1):119-23. Epub 2009 Feb 28.

55. Pombo M, Bradley JP. Proximal hamstring avulsion injuries: a technique note on surgical repairs. Sports Health. 2009 May;1(3):261-4.

56. Wood DG, Packham I, Trikha SP, Linklater J. Avulsion of the proximal hamstring origin. J Bone Joint Surg Am. 2008 Nov;90(11):2365-74.

57. Hägglund M, Waldén M, Ekstrand J. Lower reinjury rate with a coach-controlled rehabilitation program in amateur male soccer: a randomized controlled trial. Am J Sports Med. 2007 Sep;35(9):1433-42. Epub 2007 Mar 16.

58. van der Made AD, Reurink G, Gouttebarge V, Tol JL, Kerkhoffs GM. Outcome after surgical repair of proximal hamstring avulsions: a systematic review. Am J Sports Med. 2015 Nov;43(11):2841-51. Epub 2014 Nov 10.

59. Folsom GJ, Larson CM. Surgical treatment of acute versus chronic complete proximal hamstring ruptures: results of a new allograft technique for chronic reconstructions. Am J Sports Med. 2008 Jan;36(1):104-9. Epub 2007 Nov 30.

60. Moon JK, Kim YH, Park KC, Choi JH, Yang JH. Apophyseal avulsion fracture of ischial tuberosity during soccer: a case report and literature review. Korean J Sports Med. 2017 Dec 7;35(3):202-5.

61. Gidwani S, Jagiello J, Bircher M. Avulsion fracture of the ischial tuberosity in adolescents—an easily missed diagnosis. BMJ. 2004 Jul 10;329(7457): 99-100.

62. Gidwani S, Bircher MD. Avulsion injuries of the hamstring origin - a series of 12 patients and management algorithm. Ann R Coll Surg Engl. 2007 May;89(4): 394-9.

63. Colosimo A, Wyatt HM, Frank KA, Mangine RE. Hamstring avulsion injuries. Oper Tech Sports Med. 2005 Jan;13(1):80-8.

64. Tyler TF, Schmitt B, Gellert JM, McHugh MP. Eccentric strengthening at long muscle lengths reduces hamstring strain recurrences: results of long term follow-up. Orthop J Sports Med. 2014 Jul;2(2 Suppl).

65. Petersen J, Thorborg K, Nielsen MB, Budtz-Jørgensen E, Hölmich P. Preventive effect of eccentric training on acute hamstring injuries in men's soccer: a cluster-randomized controlled trial. Am J Sports Med. 2011 Nov;39(11):2296-303. Epub 2011 Aug 8.

66. Bahr R, Thorborg K, Ekstrand J. Evidence-based hamstring injury prevention is not adopted by the majority of Champions League or Norwegian Premier League football teams: the Nordic Hamstring survey. Br J Sports Med. 2015 Nov;49(22): 1466-71. Epub 2015 May 20.

67. Askling C, Karlsson J, Thorstensson A. Hamstring injury occurrence in elite soccer players after preseason strength training with eccentric overload. Scand J Med Sci Sports. 2003 Aug;13(4):244-50.

68. Schmitt B, Tim T, McHugh M. Hamstring injury rehabilitation and prevention of reinjury using lengthened state eccentric training: a new concept. Int J Sports Phys Ther. 2012 Jun;7(3):333-41.

69. Sherry MA, Best TM. A comparison of 2 rehabilitation programs in the treatment of acute hamstring strains. J Orthop Sports Phys Ther. 2004 Mar; 34(3):116-25.

70. Gabbe BJ, Bennell KL, Finch CF. Why are older Australian football players at greater risk of hamstring injury? J Sci Med Sport. 2006 Aug;9(4):327-33. Epub 2006 May 4.

71. Arnason A, Andersen TE, Holme I, Engebretsen L, Bahr R. Prevention of hamstring strains in elite soccer: an intervention study. Scand J Med Sci Sports. 2008 Feb;18(1):40-8. Epub 2007 Mar 12.

72. Matthews MJ, Jones P, Cohen D, Matthews H. The assisted Nordic hamstring curl. Strength Condit J. 2015 Feb;37(1):84-7.

73. Kraemer R, Knobloch K. A soccer-specific balance training program for hamstring muscle and patellar and achilles tendon injuries: an intervention study in premier league female soccer. Am J Sports Med. 2009 Jul;37(7): 1384-93.

74. Söderman K, Alfredson H, Pietilä T, Werner S. Risk factors for leg injuries in female soccer players: a prospective investigation during one out-door season. Knee Surg Sports Traumatol Arthrosc. 2001 Sep;9(5):313-21.

75. Emery CA, Rose MS, McAllister JR, Meeuwisse WH. A prevention strategy to reduce the incidence of injury in high school basketball: a cluster randomized controlled trial. Clin J Sport Med. 2007 Jan;17(1):17-24.

76. Fournier-Farley C, Lamontagne M, Gendron P, Gagnon DH. Determinants of return to play after the nonoperative management of hamstring injuries in athletes: a systematic review. Am J Sports Med. 2016 Aug;44(8):2166-72. Epub 2015 Dec 15.

77. Askling CM, Tengvar M, Thorstensson A. Acute hamstring injuries in Swedish elite football: a prospective randomised controlled clinical trial comparing two rehabilitation protocols. Br J Sports Med. 2013 Oct;47(15):953-9. Epub 2013 Mar 27.

78. Warren P, Gabbe BJ, Schneider-Kolsky M, Bennell KL. Clinical predictors of time to return to competition and of recurrence following hamstring strain in elite Australian footballers. Br J Sports Med. 2010 May;44(6):415-9. Epub 2008 Jul 24.

79. Mohamad Shariff HA, Ashril Y, Mohamed Razif MA. Pattern of muscle injuries and predictors of return-to-play duration among Malaysian athletes. Singapore Med J. 2013 Oct;54(10):587-91.

80. Comin J, Malliaras P, Baquie P, Barbour T, Connell D. Return to competitive play after hamstring injuries involving disruption of the central tendon. Am J Sports Med. 2013 Jan;41(1):111-5. Epub 2012 Oct 30.

81. Cohen SB, Towers JD, Zoga A, Irrgang JJ, Makda J, Deluca PF, Bradley JP. Hamstring injuries in professional football players: magnetic resonance imaging correlation with return to play. Sports Health. 2011 Sep;3(5):423-30.

82. Connell DA, Schneider-Kolsky ME, Hoving JL, Malara F, Buchbinder R, Koulouris G, Burke F, Bass C. Longitudinal study comparing sonographic and MRI assessments of acute and healing hamstring injuries. AJR Am J Roentgenol. 2004 Oct; 183(4):975-84.

83. Koulouris G, Connell DA, Brukner P, Schneider-Kolsky M. Magnetic resonance imaging parameters for assessing risk of recurrent hamstring injuries in elite athletes. Am J Sports Med. 2007 Sep;35(9):1500-6. Epub 2007 Apr 10.

84. Kilcoyne KG, Dickens JF, Keblish D, Rue JP, Chronister R. Outcome of grade I and II hamstring injuries in intercollegiate athletes: a novel rehabilitation protocol. Sports Health. 2011 Nov;3(6):528-33.

85. Reurink G, Goudswaard GJ, Tol JL, Verhaar JA, Weir A, Moen MH. Therapeutic interventions for acute hamstring injuries: a systematic review. Br J Sports Med. 2012 Feb;46(2):103-9. Epub 2011 Oct 28.

86. Skaara HE, Moksnes H, Frihagen F, Stuge B. Self-reported and performance-based functional outcomes after surgical repair of proximal hamstring avulsions. Am J Sports Med. 2013 Nov;41(11):2577-84. Epub 2013 Aug 29.

87. Sarimo J, Lempainen L, Mattila K, Orava S. Complete proximal hamstring avulsions: a series of 41 patients with operative treatment. Am J Sports Med. 2008 Jun;36(6):1110-5. Epub 2008 Mar 4.

88. Binkley JM, Stratford PW, Lott SA, Riddle DL; North American Orthopaedic Rehabilitation Research Network. The Lower Extremity Functional Scale (LEFS): scale development, measurement properties, and clinical application. Phys Ther. 1999 Apr;79(4):371-83.

89. Maniar N, Shield AJ, Williams MD, Timmins RG, Opar DA. Hamstring strength and flexibility after hamstring strain injury: a systematic review and meta-analysis. Br J Sports Med. 2016 Aug;50(15):909-20. Epub 2016 Apr 13.

90. Sole G, Milosavljevic S, Nicholson HD, Sullivan SJ. Selective strength loss and decreased muscle activity in hamstring injury. J Orthop Sports Phys Ther. 2011 May; 41(5):354-63. Epub 2011 Feb 2.

91. Tol JL, Hamilton B, Eirale C, Muxart P, Jacobsen P, Whiteley R. At return to play following hamstring injury the majority of professional football players have residual isokinetic deficits. Br J Sports Med. 2014 Sep;48(18):1364-9. Epub 2014 Feb 3.

92. Chahal J, Bush-Joseph CA, Chow A, Zelazny A, Mather RC 3rd, Lin EC, Gupta D, Verma NN. Clinical and magnetic resonance imaging outcomes after surgical repair of complete proximal hamstring ruptures: does the tendon heal? Am J Sports Med. 2012 Oct;40(10):2325-30. Epub 2012 Aug 6.

93. Brucker PU, Imhoff AB. Functional assessment after acute and chronic complete ruptures of the proximal hamstring tendons. Knee Surg Sports Traumatol Arthrosc. 2005 Jul;13(5):411-8. Epub 2004 Dec 16.

94. Wright JG. Revised grades of recommendation for summaries or reviews of orthopaedic surgical studies. J Bone Joint Surg Am. 2006 May;88(5):1161-2.